

MAINTENANCE OF WARFARIN ANTICOAGULATION FOR PATIENTS UNDERGOING VITREORETINAL SURGERY

BY Pouya N. Dayani MD, AND M. Gilbert Grand MD*

ABSTRACT

Purpose: The purpose of this study was to evaluate the risk of hemorrhagic complications associated with vitreoretinal surgery in patients in whom warfarin therapy was continued throughout the surgical period.

Methods: A review of 1,737 consecutive charts of patients undergoing pars plana vitrectomy was conducted. Inclusion criteria included patients on warfarin therapy whose international normalized ratio (INR) was elevated above normal on the day of vitreoretinal surgery. The occurrence of intraoperative and postoperative hemorrhagic complications was documented.

Results: The retrospective review detected 54 patients who underwent 57 vitreoretinal surgical procedures while on warfarin therapy. Group S consisted of patients whose INR ranged from 1.2 to 1.49, values that were considered to be subtherapeutic. Group B had INR values ranging from 1.5 to 1.99, values that were considered to be borderline therapeutic. Group T had INRs ranging from 2.0 to 2.49, values that were considered therapeutic. Group HT had INRs of 2.5 or greater, values that were considered highly therapeutic.

No patients experienced anesthesia-related or intraoperative hemorrhagic complications. Four procedures (7.0%) were complicated by postoperative hemorrhage. Two of 26 eyes (7.7%) in group S and two of 12 eyes (16.7%) in group HT experienced postoperative hemorrhages. All hemorrhagic complications cleared without additional therapy.

Conclusions: Our findings suggest that many patients may safely undergo vitreoretinal surgery while maintaining therapeutic levels of warfarin anticoagulation. We found no intraoperative hemorrhagic complications. Those hemorrhagic complications that occurred postoperatively resolved spontaneously without persistent visual sequelae or the need for supplemental surgery.

Trans Am Ophthalmol Soc 2006;104:149-160

INTRODUCTION

Warfarin (Coumadin) anticoagulation is generally used for the management of potentially life-threatening diseases. The effect of warfarin anticoagulation on vitreoretinal surgery is largely unknown. Maintenance of anticoagulation during surgery may be associated with an increased risk of intraoperative or postoperative hemorrhage. Yet, discontinuation may subject patients to the risk of systemic complications such as embolic disease or cerebrovascular accident. Therefore, decisions regarding maintenance, modification, or perioperative discontinuation of anticoagulation therapy pose a significant dilemma for the ophthalmic surgeon. The purpose of this study is to provide further information regarding the results of vitreoretinal surgery in patients in whom warfarin therapy was continued throughout the surgical period.

METHODS

Approval was granted by the Washington University Medical Center Human Studies Committee for a retrospective review of patient charts. The charts of 1,737 consecutive patients who underwent pars plana vitrectomy performed by surgeons of the Barnes Retina Institute during the period of January 1, 2004, through December 20, 2005, were reviewed. Inclusion criteria included those patients on warfarin therapy whose international normalized ratio (INR) and prothrombin time (PT) were elevated above normal values on the day of vitreoretinal surgery. Surgical procedures that occurred prior to 2004 on the identified patients were also included if patients had an elevated INR value at the time of that procedure. Concomitant use of other anticoagulants, such as clopidogrel (Plavix) and aspirin, was noted. Data collected included age; gender; the etiologic agent for which warfarin anticoagulation therapy was employed; the preoperative vitreoretinal diagnosis for which surgery was indicated; the type of surgery, including vitreous technique and the use of additional surgical techniques, such as scleral buckling; and the method of anesthesia subdivided into general anesthesia or local infiltration with monitored anesthesia care (MAC). Preoperative and postoperative nonstandardized Snellen visual acuity was determined. The INR at the time of surgery was collected, and PT and partial thromboplastin time (PTT) were recorded when available. The occurrence of intraoperative and postoperative hemorrhagic complications, defined as bleeding that occurred within 1 month following surgery, was documented.

RESULTS

The retrospective review of records detected 54 patients who underwent 57 vitreoretinal surgical procedures while on warfarin anticoagulation therapy. The records of these patients were subdivided into four groups based on the INR values obtained on the day of surgery. Group S consisted of patients whose INR ranged from 1.2 to 1.49, values that were considered to be subtherapeutic.

From Washington University School of Medicine, St Louis, Missouri (Dr Dayani and Dr Grand), and Barnes Retina Institute, St Louis, Missouri (Dr Grand).

*Presenter.

Bold type indicates  member.

Group B had INRs ranging from 1.5 to 1.99, values that were considered to be borderline therapeutic. Group T had INRs ranging from 2.0 to 2.49, values that were considered therapeutic. Group HT had INRs of 2.5 or greater, values that were considered highly therapeutic.

GROUP S (SUBTHERAPEUTIC)

There were 24 patients undergoing 26 vitreoretinal procedures who had a mean INR equal to 1.30 (range, 1.2 to 1.49). Patients in this group had a mean PT of 16.0 seconds (range, 15.0 to 17.5 seconds). One patient had an abnormal PTT equal to 38.8 seconds (normal, 35.0). Patients taking concomitant medications associated with prolonged bleeding included one taking aspirin and two taking clopidogrel. The group included 15 men and nine women with a mean age of 72 years (range, 51 to 93 years) (Table 1).

TABLE 1. HEMORRHAGIC COMPLICATIONS RELATED TO VITREORETINAL SURGERY: GROUP S (SUBTHERAPEUTIC)*

AGE	INR	ABNORMAL PTT OR ASSOCIATED MEDICATION	REASON FOR WARFARIN	OCULAR DIAGNOSIS	SURGERY	POSTOP COMPLICATIONS
76	1.20		Atrial fibrillation	VH – PDR	PPV	None
75	1.50		Unknown	ERM	PPV, MP, SOR	None
55	1.20		Atrial fibrillation	ERM	PPV, MP	None
79	1.22		Atrial fibrillation	ERM	PPV, MP	None
73	1.28		Atrial fibrillation	MH	PPV	None
74	1.28		Atrial fibrillation	MH	PPV, MP	None
69	1.36		Atrial fibrillation	MH	PPV, MP	None
82	1.32	Aspirin	Prosthetic valves	Chronic vitritis	PPV	None
93	1.30		Unknown	VH – exudative AMD	PPV, MP, SO	None
68	1.30		Unknown	VH – retinal tear	PPV, MP	None
78	1.30		Atrial fibrillation	ERM	PPV, MP	None
75	1.30		Atrial fibrillation	VH, PDR	PPV	None
75	1.48		DVT/PE	MH	PPV, MP	None
74	1.30		Atrial fibrillation	MH	PPV, MP	None
53	1.30		CABG	TRD, PDR	PPV, MP	None
79	1.28		Atrial fibrillation	Sub heme – AMD	FNA BX, PPV, Cryo	Recurrent VH†
88	1.47		Atrial fibrillation	RD	PPV, lens fragments, SO	None
78	1.29	38.8	Unspecified arrhythmia	Sub heme – AMD	PPV	None

TABLE 1 (CONTINUED). HEMORRHAGIC COMPLICATIONS RELATED TO VITREORETINAL SURGERY: GROUP S (SUBTHERAPEUTIC)*

AGE	INR	ABNORMAL PTT OR ASSOCIATED MEDICATION	REASON FOR WARFARIN	OCULAR DIAGNOSIS	SURGERY	POSTOP COMPLICATIONS
77	1.40	Plavix	Atrial fibrillation	Chronic vitritis	PPV	None
79	1.25	Plavix	Atrial fibrillation	Sub heme – AMD	PPV, SPA	None
56	1.24		Atrial fibrillation	VH – RD	PPV, SB	None
57	1.41	Aspirin	Prosthetic valves	VH - PDR	PPV, MP	Dense VH‡ Recurrent VH§
72	1.30		Atrial fibrillation	VH – CRVO	PPV, MP	None
56	1.30		Atrial fibrillation	ERM	PPV, MP	None
78	1.20		Prosthetic valves	ERM	PPV, MP	None
51	1.20		DVT	VH – PDR	PPV, MP	None

AMD = age-related macular degeneration; CABG = coronary artery bypass graft; Cryo = cryoretinopexy; CRVO = central retinal vein occlusion; DVT = deep vein thrombosis; ERM = epiretinal membrane; FNA BX = fine-needle biopsy; INR = international normalized ratio; MH = macular hole; MP = membrane peel; PDR = proliferative diabetic retinopathy; PE = pulmonary embolism; PPV = pars plana vitrectomy; PTT = partial thromboplastin time; RD = retinal detachment; SB = scleral buckle; SO = silicone oil; SOR = silicone oil removal; SPA = subretinal tissue plasminogen activator; Sub heme = subretinal hemorrhage; TRD = traction retinal detachment; VH = vitreous hemorrhage.

*INR value, 1.2 to 1.49.

‡Recurrent VH on postoperative day 1, no additional follow-up.

‡Dense VH at postoperative week 2; cleared spontaneously.

§Recurrent VH at week 7 postsurgery; cleared to 20/80.

The underlying systemic etiologies requiring warfarin anticoagulation included atrial fibrillation (14), cardiac valve surgery (3), deep vein thrombosis (2), coronary artery disease status post bypass (1), unspecified cardiac arrhythmia (1), and unknown (3).

The preoperative vitreoretinal diagnoses included vitreous hemorrhage (8), of which four were attributed to proliferative diabetic retinopathy, two had an associated tear and retinal detachment, one had associated central retinal vein occlusion, and one had hemorrhage secondary to exudative age-related macular degeneration. The remaining surgical indications included epiretinal membrane (6), macular hole (5), subretinal hemorrhage associated with age-related macular degeneration (3), chronic vitritis (2), retinal detachment (1), and diabetic retinopathy with retinal detachment (1).

Twenty-five eyes underwent pars plana vitrectomy. Of these, 16 eyes had vitrectomy associated with membrane peeling, one had an additional scleral buckling procedure, and one underwent administration of subretinal tissue-type plasminogen activator (tPA). One eye underwent a combination of fine-needle biopsy aspiration as well as vitrectomy. Five procedures were managed using general anesthesia and 21 with local infiltration of anesthesia and MAC. A standard three-port 20-gauge pars plana vitrectomy was used for 24 eyes, and 25-gauge vitrectomy was used for two. Preoperative visual acuity ranged from 20/40 to light perception, and postoperative acuity ranged from 20/25 to hand motions. Preoperative and postoperative distribution of acuities is shown in Figure 1.

There were no intraoperative or anesthetic complications. One patient had a recurrent vitreous hemorrhage on the first postoperative day. No additional follow-up was available. This patient's INR was 1.28 at the time of surgery for an extramacular subretinal hematoma with overlying vitreous hemorrhage. The surgical procedure included fine-needle biopsy aspiration as well as vitrectomy. A second patient with an INR value of 1.41 had a recurrent vitreous hemorrhage 2 weeks following surgery for proliferative diabetic retinopathy with vitreous hemorrhage. The surgical procedure performed was vitrectomy with membrane peeling, peripheral cryopexy, and endolaser. The hemorrhage spontaneously cleared; however, at 7 weeks postoperatively, this patient experienced a second vitreous hemorrhage, which also spontaneously cleared (Table 1).

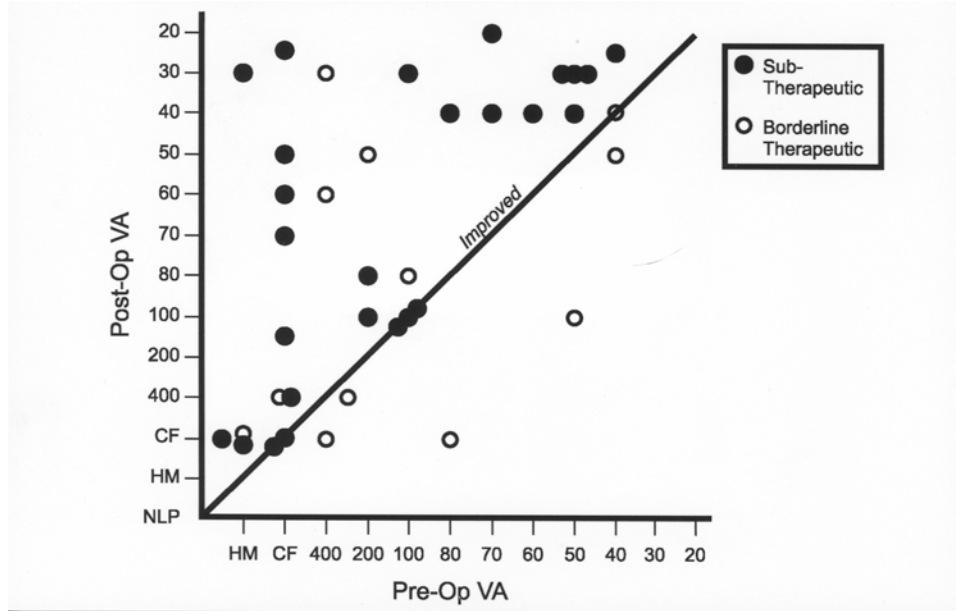


FIGURE 1

Visual results following vitreoretinal surgery in patients on warfarin therapy. International normalized ratio indicates subtherapeutic or borderline therapeutic level of anticoagulation. CF = counting fingers, HM = hand motions, NLP = no light perception, VA = visual acuity.

GROUP B (BORDERLINE THERAPEUTIC)

There were 11 patients undergoing 12 vitreoretinal procedures who had a mean INR equal to 1.7 (range, 1.5 to 1.99). Patients in this group had a mean PT of 19.9 seconds (range, 17.7 to 21.9).

Four patients also had an abnormal PTT with values ranging from 35.6 to 46.8 seconds (normal, <35.0). Concomitant medications included aspirin in one patient and clopidogrel in one. The group included nine men and two women with a mean age of 73 years (range, 41 to 85 years) (Table 2).

TABLE 2. HEMORRHAGIC COMPLICATIONS RELATED TO VITREORETINAL SURGERY: GROUP B (BORDERLINE THERAPEUTIC)*

AGE	INR	ABNORMAL PTT OR OTHER MEDICATION	REASON FOR WARFARIN	OCULAR DIAGNOSIS	SURGERY	POSTOP COMPLICATIONS
75	1.56		Unknown	RD – ruptured globe	PPV, MP, SO	None
54	1.60		Atrial fibrillation	Silicone oil removal	SO removal	None
84	1.70		Unspecified arrhythmia	ERM	PPV, MP	None
85	1.77		Atrial fibrillation	RD	PPV, SB	None
82	1.74		Unknown	RD	PPV	None
69	1.80		Atrial fibrillation	RD	PPV	None

TABLE 2 (CONTINUED). HEMORRHAGIC COMPLICATIONS RELATED TO VITREORETINAL SURGERY: GROUP B (BORDERLINE THERAPEUTIC)*

AGE	INR	ABNORMAL PTT OR OTHER MEDICATION	REASON FOR WARFARIN	OCULAR DIAGNOSIS	SURGERY	POSTOP COMPLICATIONS
69	1.80		Atrial fibrillation	TRD	PPV, PPL, MP, SB, SO	None
41	1.99	43.1	Prosthetic valves	RD – dislocated lens	PPV, PPL, SO	None
78	1.50	46.8, Plavix	Atrial fibrillation	Chronic vitritis	Vit. biopsy, PPV	None
83	1.77	35.6	DVT/PE	VH-PVD	PPV	None
75	1.60	37.1	DVT/PE	ERM	PPV, MP	None
85	1.70	Aspirin	CABG	RD	PPV	None

CABG = coronary artery bypass graft; DVT = deep vein thrombosis; ERM = epiretinal membrane; INR = international normalized ratio; MP = membrane peel; PE = pulmonary embolism; PPL = pars plana lensectomy; PPV = pars plana vitrectomy; PTT = partial thromboplastin time; PVD = posterior vitreous detachment; RD = retinal detachment; SB = scleral buckle; SO = silicone oil; VH = vitreous hemorrhage; Vit = vitreous.

*INR value, 1.5 to 1.99.

The underlying systemic etiologies requiring warfarin anticoagulation included atrial fibrillation (4), cardiac valve surgery (1), deep vein thrombosis with pulmonary embolism (2), aortic aneurysms and coronary artery bypass surgery (1), unspecified arrhythmia (1), and unknown (2).

The preoperative vitreoretinal diagnoses included vitreous hemorrhage (1), retinal detachment (6), epiretinal membrane (2), chronic vitritis (1), tractional retinal detachment (1), and retained silicone oil (1). Eleven eyes underwent pars plana vitrectomy procedures; four were associated with membrane peeling, two with scleral buckling, and two with pars plana lensectomy. One patient underwent vitrectomy for silicone oil removal. General anesthesia was used in four patients, with local infiltration anesthesia (MAC) in eight. Surgical technique involved standard three-port 20-gauge pars plana vitrectomy in 11 procedures and 25-gauge vitrectomy in one.

Preoperative visual acuity ranged from 20/40 to hand motions, and postoperative visual acuity ranged from 20/40 to counting fingers. Distribution of preoperative and postoperative visual acuities is shown in Figure 1.

There were no anesthetic complications, and no patients in this group developed intraoperative or postoperative hemorrhagic complications.

GROUP T (THERAPEUTIC)

There were seven patients undergoing a total of seven vitreoretinal procedures, who had a mean INR equal to 2.1 (range, 2.0 to 2.49). The mean PT was 24.0 seconds (range, 22.8 to 26.0 seconds). One patient had an abnormal PTT of 46.1 seconds (normal, <35.0). Concomitant medications included aspirin in one patient, celecoxib (Celebrex) in two, and rofecoxib (Vioxx) in one. The group consisted of five males and two females with a mean age of 58 years and a median age of 68 years (range, 8 to 72 years) (Table 3).

The underlying systemic etiologies requiring warfarin anticoagulation included atrial fibrillation (2), deep vein thrombosis (1), heart transplant with a prosthetic valve (1), cardiac valve surgery (1), and unknown (2). The preoperative vitreoretinal diagnoses included retinal detachment (6) and retained silicone oil (1). The surgical procedure employed was pars plana vitrectomy in six patients, with associated membrane peel in five, scleral buckling in four, and lensectomy in one. One patient underwent silicone oil removal by means of pars plana vitrectomy. The surgical technique involved standard three-port 20-gauge vitrectomy in all patients. General anesthesia was used in three patients and local infiltrative anesthesia (MAC) in four. Preoperative visual acuity ranged from 20/25 to counting fingers, and postoperative visual acuity ranged from 20/20 to no light perception. Distribution of preoperative and postoperative acuities is shown in Figure 2.

There were no anesthetic complications, and no patients in this group developed intraoperative or postoperative hemorrhages.

GROUP HT (HIGHLY THERAPEUTIC)

Twelve patients who underwent 12 vitreoretinal procedures had a mean INR of 2.8 (range, 2.5 to 3.6). Patients in this group had a mean PT of 29.4 seconds (range, 26.3 to 36.4 seconds). Six patients had an associated abnormal PTT with values ranging from 40.2

to 73.4 seconds. Concomitant medicines included aspirin in one patient and celecoxib in one. The group included 10 men and two women with a mean age of 67 years (range, 42 to 79 years) (Table 4).

TABLE 3. HEMORRHAGIC COMPLICATIONS RELATED TO VITREORETINAL SURGERY: GROUP T (THERAPEUTIC)*

AGE	INR	ABNORMAL PTT OR OTHER MEDICATION	REASON FOR WARFARIN	OCULAR DIAGNOSIS	SURGERY	POSTOP COMPLICATIONS
68	2.00		Unknown	RD	PPV, MP, SO	None
72	2.10	Celebrex	DVT	RD	PPV, SB, MP	None
8	2.09		Prosthetic valve, history of heart transplant	RD	PPV, PPL, SB, MP, SO	None
54	2.10	46.1; Vioxx	Atrial fibrillation	RD	PPV, SB, MP, SO	None
63	2.20	Celebrex	Prosthetic valves	SO removal	SO removal	None
72	2.40			RD	PPV, MP	None
70	2.10	Aspirin	Atrial fibrillation	RD	PPV, SB	None

DVT = deep vein thrombosis; INR = international normalized ratio; MP = membrane peel; PPL = pars plana lensectomy; PPV = pars plana vitrectomy; PTT = partial thromboplastin time; RD = retinal detachment; SB = scleral buckle; SO = silicone oil.

*INR value, 2.0 to 2.49.

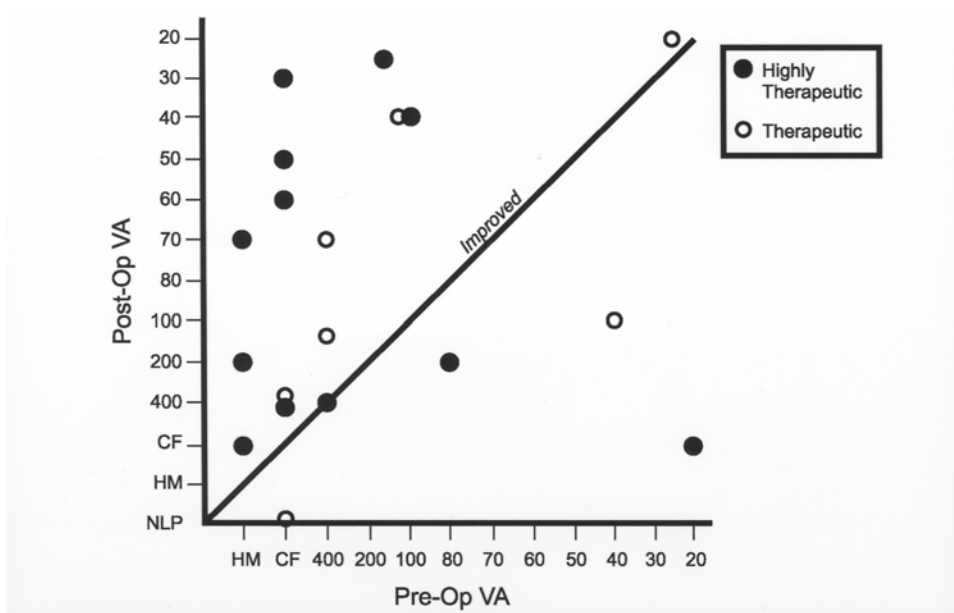


FIGURE 2

Visual results following vitreoretinal surgery in patients on warfarin therapy. International normalized ratio indicates therapeutic or highly therapeutic levels of anticoagulation. CF = counting fingers, HM = hand motions, NLP = no light perception, VA = visual acuity.

TABLE 4. HEMORRHAGIC COMPLICATIONS RELATED TO VITREORETINAL SURGERY: GROUP HT (HIGHLY THERAPEUTIC)*

AGE	INR	ABNORMAL PTT OR OTHER MEDICATION	REASON FOR WARFARIN	OCULAR DIAGNOSIS	SURGERY	POSTOP COMPLICATIONS
79	2.50		Atrial fibrillation	ERM	PPV, MP	None
66	2.50		DVT/PE	RD	PPV, SB	None
66	2.50		Unspecified arrhythmia	Retained lens fragment	PPV, Removal lens fragment	None
63	2.69	Celebrex	Prosthetic valves	RD	PPV, SO	None
68	2.70	73.4	DVT/PE	RD	PPV	None
72	2.70		Atrial fibrillation	VH	PPV	None
64	2.68		Prosthetic valves	VH – PDR	PPV, MP	Recurrent VH†
70	3.60	61.4	DVT/PE	VH – PDR	PPV	None
42	2.83	48.6	Prosthetic valves	RD	SO removal, PPV, SO	None
73	3.26	40.2; Aspirin	Atrial fibrillation	Macular edema	PPV, MP	None
69	2.69	55.3	Atrial fibrillation	VH – PDR, + hyphema	PPV, anterior chamber washout	VH, hyphema, nasal choroidal detachment‡
75	2.53	41.9	Atrial fibrillation	RD	PPV	None

DVT = deep vein thrombosis; ERM = epiretinal membrane; INR = international normalized ratio; MP = membrane peel; PDR = proliferative diabetic retinopathy; PE = pulmonary embolism; PPV = pars plana vitrectomy; PTT = partial thromboplastin time; RD = retinal detachment; SB = scleral buckle; SO = silicone oil; VH = vitreous hemorrhage.

*INR value, >2.49.

†Recurrent VH postoperative week 1, resolved without therapy.

‡VH, hyphema and nasal choroidal detachment on postoperative day 7, cleared spontaneously.

The underlying systemic etiology requiring anticoagulation was atrial fibrillation (5), deep vein thrombosis/pulmonary embolism (3), valve replacement surgery (3), and an unspecified arrhythmia (1). The preoperative vitreoretinal diagnoses included retinal detachment in five patients, one of whom had an associated vitreous hemorrhage, and vitreous hemorrhage without retinal detachment in four patients, three of whom had proliferative diabetic retinopathy. One patient with proliferative diabetic retinopathy had iris neovascularization with secondary glaucoma and hyphema. Other diagnoses included epiretinal membrane (1), retained lens fragments (1), and macular edema (1). The surgical procedure performed was pars plana vitrectomy in all 12 patients, with associated membrane peeling in three, removal of lens fragments in one, anterior chamber washout in one, and scleral buckling in one. The surgical technique was standard three-port 20-gauge pars plana vitrectomy in 11 patients and 25-gauge vitrectomy in one. General anesthesia was used in one patient, and 11 patients underwent local infiltrative anesthesia (MAC).

Preoperative visual acuity ranged from 20/20 to light perception, and postoperative visual acuity ranged from 20/25 to counting fingers. Distribution of preoperative and postoperative visual acuities is shown in Figure 2.

In this group, there were no anesthetic complications, and no patients experienced intraoperative hemorrhagic complications. Postoperatively, two patients (17%) were noted to have an intraocular hemorrhage. One patient with an INR of 2.68 and a normal PTT underwent surgery for proliferative retinopathy with vitreous hemorrhage. This patient had hemorrhage in the inferior vitreous cavity at 1 week postoperatively that spontaneously resolved without therapy over the ensuing 2 months. A second patient with an INR value of 2.69 underwent surgery for proliferative diabetic retinopathy with iris neovascularization, hyphema, and vitreous

hemorrhage. This patient had vitreous hemorrhage and hyphema postoperatively. It was unclear whether this hemorrhage represented residual or recurrent bleeding. A nasal choroidal detachment was also noted on the first postoperative day; however, it was not determined whether the detachment was hemorrhagic or serous. The hyphema, vitreous hemorrhage, and choroidal detachment resolved spontaneously without additional treatment.

DISCUSSION

Warfarin is an anticoagulant typically used in patients with atrial fibrillation, venous thromboembolism, mechanical or diseased heart valves, cardioembolic cerebroischemic events, and acute myocardial infarction. The anticoagulant effect of warfarin is mediated through inhibition of the vitamin K-dependent gamma-carboxylation of coagulation factors II, VII, IX, and X.^{1,2} The full anticoagulant effect of warfarin may be delayed for 36 to 72 hours after administration until the normal clotting factors have been cleared from the patient's circulation.³ Upon initiation of therapy, warfarin can create a biochemical paradox by producing an anticoagulant effect due to inhibition of procoagulants, while also producing a potentially thrombogenic effect by impairing the synthesis of naturally occurring inhibitors of coagulation, such as proteins C and S.⁴ Warfarin is strongly protein-bound; any agent that also binds to albumin may displace warfarin and increase its biological activity.

The laboratory test most commonly used to monitor warfarin therapy is the one-stage PT, which is sensitive to reduced activity of factors II, VII, and X. This test utilizes thromboplastin to activate clotting in blood specimens. There are many different commercially available thromboplastins that are typically derived from extracts of lung, brain, or placenta. Different thromboplastins yield varied PT responses to warfarin-induced anticoagulation. Different makes and models of coagulation analyzers may also affect PT values. Consequently, PT values do not reliably agree between laboratories and are not suitable for defining therapeutic ranges for warfarin therapy. The INR was developed to standardize PT values so that test results from different thromboplastins and coagulation analyzers would be equivalent. Under the INR system, the thromboplastin is assigned an international sensitivity index (ISI) value. The ISI indicates the relative sensitivity of the thromboplastin compared to an international reference thromboplastin. The ISI, the patient's PT, and the mean normal PT, which is a value derived in each laboratory by averaging at least 20 normal individuals, are used to calculate the INR.

The targeted INR value for patients being treated for acute myocardial infarction, atrial fibrillation, venous thromboembolism, and bioprosthetic cardiac valves is typically 2.5. The INR goal for patients with mechanical valves or for patients with lupus inhibitor and recurrent thromboembolism is typically 3.0. Some patients may experience spontaneous bleeding during warfarin therapy. Such patients typically have one or more of the following characteristics: age greater than 75 years, poorly controlled hypertension, liver disease, poor drug compliance, presence of bleeding lesions or disorders, concomitant use of nonsteroidal anti-inflammatory drugs (NSAIDs), and instability of INR control or INR greater than 3.0.⁵⁻⁷ In general, the risk of major bleeding episodes in patients treated with warfarin is thought to be related to the degree of anticoagulation. Studies in patients with atrial fibrillation indicate that risk of bleeding increases substantially at INR values above 4.0.^{8,9}

When planning elective surgery, the surgeon must consider the alternatives of maintenance, modification, or discontinuation of anticoagulation. It is of singular importance to evaluate the rationale for which the patient is being anticoagulated. Patients at low risk of thromboembolic disease include those with a history of deep vein thrombosis (DVT) after more than 3 months without high risk factors, nonvalvular atrial fibrillation, or cardiomyopathy without atrial fibrillation. Those at high risk of thromboembolic disease are patients with hypercoagulable states, mechanical valves, DVT with high risk factors or of recent history, or atrial fibrillation with high risk factors such as a history of prior thromboembolic episodes, heart failure, left ventricular dysfunction, mitral stenosis, thyroid disease, or age greater than 75 years with a history of diabetes or hypertension.^{10,11} The consequences of arterial thromboembolism are much more serious than those of the venous circulation, with 20% of episodes being fatal and 40% causing permanent disability.^{12,13}

Commercially available warfarin has a biologic half-life of 36 to 42 hours. After cessation of oral warfarin, it typically requires several days for the INR to fall below 2.0. One study prospectively evaluated 22 patients with a baseline INR of 2.6, in whom it was considered safe to discontinue warfarin therapy.¹⁴ The INR fell to 1.6 at 2.7 days and 1.2 at 4.7 days. Following reinstatement of warfarin therapy, it takes approximately 3 to 4 days for the INR to rise above 2.0. It is therefore estimated that if warfarin is withheld for 4 days prior to surgery and treatment is started as soon as possible following the surgical procedure, the patient will have a subtherapeutic INR for approximately 2 days before surgery and 2 days postoperatively.¹⁴⁻¹⁶

There is no current consensus regarding the management of patients undergoing elective surgery while on long-term anticoagulation therapy. The primary concern associated with discontinuation of anticoagulation prior to surgery is the increased risk of thromboembolism and cerebrovascular accident. There is also concern regarding life-threatening rebound hypercoagulability following the abrupt cessation of anticoagulation.¹⁷⁻¹⁹ These concerns need to be weighed against the potential for hemorrhagic complications that may occur during or following surgery.

Maintenance of anticoagulation has been shown to be safe in elective, nonocular surgical procedures. In one series of patients undergoing cholecystectomy or gastric resection, there was no difference in blood loss between patients that were anticoagulated and those that were not.²⁰ Anticoagulation has also been shown to be safe in patients undergoing dental extraction.^{21,22}

Kallio and associates²³ studied the risk of hemorrhagic complications related to ocular anesthesia. In a series of 1,383 patients undergoing intraocular surgery, 482 patients were using preoperative acetylsalicylic acid, 260 patients were taking NSAIDs, and 76 patients were on warfarin. This study showed no predisposition to hemorrhage associated with either retrobulbar or peribulbar anesthesia.

Current reports concerning the risk of hemorrhagic ocular complications with ophthalmic surgery in patients on anticoagulation are mixed. Some studies have found an increased risk of bleeding,²⁴⁻²⁷ whereas others have not.^{16,23,28-38} Most published reports suggest that warfarin therapy may be safe in patients undergoing cataract or oculoplastic surgery.^{16,23,28-38} Katz and associates,³¹ in a review of 19,283 cataract surgeries, identified 752 patients on warfarin therapy; 10.5% of these patients were advised to stop anticoagulation therapy prior to surgery. In this study, there were no ocular hemorrhages among warfarin users, whether or not treatment was discontinued within 4 days of surgery. In a series of 41 anticoagulated patients undergoing a range of 50 ophthalmic procedures, McCormack and colleagues²⁸ found no significant hemorrhagic complications associated with anesthesia or surgery. Gainey and coworkers²⁴ also reviewed the outcome of 50 patients on warfarin therapy undergoing ocular surgery. There was no significant difference in hemorrhagic complications observed among patients in whom warfarin therapy was continued and those in whom it was discontinued. Jonas and associates,³⁸ in a review of patients undergoing cataract surgery, found 21 patients on systemic anticoagulation with warfarin and found no increased risk of intraoperative or postoperative hemorrhage.

There is limited existing literature regarding the safety of vitreoretinal procedures in patients in whom aspirin therapy or warfarin anticoagulation is maintained. Flaxel and Blach³⁹ described three patients treated with aspirin who experienced intraocular hemorrhage during vitreoretinal surgery. In McCormack and associate's series²⁸ of 50 ophthalmic procedures, there were no hemorrhagic complications among the eight patients who underwent vitreoretinal surgery. In a series of 50 patients receiving warfarin anticoagulation, Gainey and coworkers²⁴ described six who underwent vitreoretinal procedures. None of these patients had hemorrhagic complications. However, Narendran and Williamson²⁵ described seven patients who underwent vitreoretinal surgery while on anticoagulation. Two of the seven suffered hemorrhagic complications, including one postoperative hemorrhagic choroidal detachment and one recurrent vitreous hemorrhage. Narendran and Williamson²⁵ concluded that warfarin anticoagulation was associated with an increased risk of hemorrhagic complications. McDonald's review of vitreoretinal surgery in patients on anticoagulation included 12 patients whose INR was 2.0 or greater (McDonald HR, Retina Subspecialty Day 2003, Abstract). One patient in this group suffered a subretinal hemorrhage during external drainage of subretinal fluid in the course of scleral buckling.

Our study describes 54 patients who underwent 57 vitreoretinal procedures. We found 35 patients who had INRs ranging from 1.2 to 1.9, values that we considered subtherapeutic. These 35 patients underwent 38 vitreoretinal procedures. There were no intraoperative hemorrhagic complications. In this group, two procedures (5%), in patients with INR values of 1.28 and 1.41, were associated with postoperative hemorrhage but required no additional surgery. There were 19 patients with an INR value of 2.0 or greater who underwent 19 vitreoretinal procedures. In this group, there were no intraoperative hemorrhagic complications. Two patients (11%), with INR values of 2.68 and 2.69, experienced postoperative hemorrhagic complications. Both resolved spontaneously, requiring no additional surgery. It is noteworthy that among the four patients with postoperative hemorrhagic complications, one had an elevated PTT value equal to 55.3 seconds and another was on concurrent aspirin therapy.

Surgical technique for the patients in our study was identical to that used in patients who were not anticoagulated. Meticulous bipolar diathermy was used to control bleeding during the initial exposure of the globe and during isolation of muscles in those patients undergoing buckling in addition to vitrectomy. Scleral buckling procedures, especially those involving encircage, require considerably more dissection with the potential for greater intraoperative bleeding. However, unusual degrees of bleeding were not encountered during such dissections in these patients. Prior to performing sclerotomies in the course of vitrectomy, episcleral vessels were diathermized. Dissection of retinal fibrovascular proliferation was accompanied by intraocular diathermy. It is possible that the postoperative hemorrhages seen in our patients were related to bleeding from sclerotomies or incisions into fibrovascular proliferative stalks. However, no such bleeding occurred intraoperatively.

Subretinal hemorrhage is a known complication of external drainage during scleral buckling procedures and may be attributable to a variety of factors, including puncture or laceration of choroidal vessels, as well as acute hypotony. McDonald described one patient who developed subretinal hemorrhage during external drainage of subretinal fluid in the course of a scleral buckling procedure (McDonald HR, Retina Subspecialty Day 2003, Abstract).

In the series presented herein, three patients with INR values of 1.2 to 1.9 underwent scleral buckling as a component of their vitreoretinal surgery; among those patients considered to have therapeutic levels of anticoagulation with INR greater than 2.0, five patients underwent scleral buckling in addition to vitrectomy. It is important to note that external drainage was not attempted in any of the patients in this series who underwent buckling in conjunction with vitrectomy. Instead, flattening of the retina was achieved with internal drainage and gas tamponade. In our series, we experienced no intraoperative bleeding associated with these measures, and no postoperative hemorrhagic complications occurred in patients who underwent scleral buckling in conjunction with vitrectomy.

In this series, in which 13 procedures were performed using general anesthesia and 44 using local infiltration of anesthesia with MAC, no anesthetic complications were encountered. The technique we employ for administration of local infiltrative anesthesia consists of topical anesthesia followed by intravenous sedation. Using a sharp 30-gauge needle, a subconjunctival injection results in elevation of a bleb of conjunctiva. A small limbal incision can then be made to allow blunt dissection of Tenon's capsule through which a blunt-tipped curved cannula may be passed into the sub-Tenon's space. Infiltration of local anesthesia can then be accomplished, resulting in adequate anesthesia and akinesia for vitreoretinal surgery, thus avoiding potential hazards of hemorrhage associated with retrobulbar injections.

The use of aspirin and NSAIDs has been postulated to increase the risk of bleeding in warfarin-treated patients by multiple mechanisms, including interference with platelet function through inhibition of cyclooxygenase-I (COX-I).⁴⁰ The use of COX-II selective NSAIDs may lead to fewer complications, because these agents do not interfere with platelet function. None of the patients in our series using COX-II therapy developed new postoperative hemorrhagic complications.

In conclusion, this is the single largest report to date of vitreoretinal surgical procedures in patients who had therapeutic levels of warfarin anticoagulation. The study is limited in that it was conducted in a retrospective fashion, the sample size is small, and there was no control group. Furthermore, we were unable to collect data regarding whether patients in this study ingested herbal supplements known to have an anticoagulation effect or to potentiate the effects of warfarin anticoagulation.⁴¹ However, it would seem logical that the concomitant use of such supplements would increase, rather than decrease, the risk of intraoperative or postoperative hemorrhage and would be unlikely to skew results toward fewer hemorrhagic complications.

Our findings suggest that many patients may safely undergo vitreoretinal surgery while maintaining therapeutic levels of warfarin anticoagulation. In our series, no patient suffered an intraoperative hemorrhagic complication. Four eyes (7.0%) experienced postoperative hemorrhages that resolved spontaneously without persistent visual sequelae or the need for supplemental surgery. The ultimate visual results for patients in this series were quite favorable (Figures 1 and 2). On the basis of these findings, when caring for patients in whom the systemic risks of cessation of anticoagulation may be substantial, ophthalmic surgeons may wish to consider undertaking vitreoretinal procedures while maintaining anticoagulation therapy. Anesthetic and surgical techniques may need to be modified or adjusted to avoid maneuvers thought to increase the risk of hemorrhage. The decision to withhold, modify, or continue anticoagulation should be individualized, taking into consideration the patient's medical history, systemic findings, and the specific surgical procedure required for management of the underlying vitreoretinal abnormality. Consultation with the physician responsible for monitoring the patient's anticoagulation is prudent. Finally, such patients must be fully informed of the risks involved with either maintenance or discontinuation of anticoagulation therapy.

REFERENCES

1. Freedman MD. Oral anticoagulants: pharmacodynamics, clinical indications and adverse effects. *J Clin Pharmacol* 1992;32:196-209.
2. Ansell J, Hirsh J, Poller L, et al. The pharmacology and management of the vitamin K antagonists: the Seventh ACCP Conference on Antithrombotic and Thrombolytic Therapy. *Chest* 2004;126:204S-223S.
3. Becker DM, Humphries JE, Walker FB, et al. Standardizing the prothrombin time. Calibrating coagulation instruments as well as thromboplastin. *Arch Pathol Lab Med* 1993;117:602-605.
4. Clouse LH, Comp PC. The regulation of hemostasis: the protein C system. *N Engl J Med* 1986;314:1298-1304.
5. Fitzmaurice DA, Blann AD, Lip GY. Bleeding risks of antithrombotic therapy. *BMJ* 2002;325:828-831.
6. Veeger NJ, Piersma-Wichers M, Tijssen JG, et al. Individual time within target range in patients treated with vitamin K antagonists: main determinant of quality of anticoagulation and predictor of clinical outcome. A retrospective study of 2300 consecutive patients with venous thromboembolism. *Br J Haematol* 2005;128:513-519.
7. Oden A, Fahlen M. Oral anticoagulation and risk of death: a medical record linkage study. *BMJ* 2002;325:1073-1075.
8. Optimal oral anticoagulant therapy in patients with nonrheumatic atrial fibrillation and recent cerebral ischemia. The European Atrial Fibrillation Trial Study Group. *N Engl J Med* 1995;333:5-10.
9. Torn M, van der Meer FJ, Rosendaal FR. Lowering the intensity of oral anticoagulant therapy: effects on the risk of hemorrhage and thromboembolism. *Arch Intern Med* 2004;164:668-673.
10. Jafri SM. Periprocedural thromboprophylaxis in patients receiving chronic anticoagulation therapy. *Am Heart J* 2004;147:3-15.
11. Dunn A. Perioperative management of patients receiving oral anticoagulants. *Arch Intern Med* 2003;163:901-908.
12. Coon WW, Willis PW. Recurrence of venous thromboembolism. *Surgery* 1973;73:823-827.
13. Risk factors for stroke and efficacy of antithrombotic therapy in atrial fibrillation. Analysis of pooled data from five randomized controlled trials. *Arch Intern Med* 1994;154:1449-1457.
14. Rockson SG, Albers GW. Comparing the guidelines: anticoagulation therapy to optimize stroke prevention in patients with atrial fibrillation. *J Am Coll Cardiol* 2004;43:929-935.
15. Kearon C, Hirsh J. Management of anticoagulation before and after elective surgery. *N Engl J Med* 1997;336:1506-1511.
16. Rotenstreich Y, Rubowitz A, Segev F, et al. Effect of warfarin therapy on bleeding during cataract surgery. *J Cataract Refract Surg* 2001;27:1344-1356.
17. Poller L, Thomson J. Evidence for "rebounds" hypercoagulability after stopping anticoagulants. *Lancet* 1964;39:62-64.
18. Palareti G, Legnani C, Guazzaloca G, et al. Activation of blood coagulation after abrupt or stepwise withdrawal of oral anticoagulants: a prospective study. *Thromb Haemost* 1994;72:222-226.
19. Genewin U, Haeberli A, Straub PW, et al. Rebound after cessation of oral anticoagulant therapy: the biochemical evidence. *Br J Haematol* 1996;92:479-485.
20. Rustad H, Myhre E. Surgery during anticoagulant treatment. The risk of increased bleeding in patients on oral anticoagulant treatment. *Acta Med Scand* 1963;173:115-119.
21. McIntyre H. Management, during dental surgery, of patients on anticoagulants. *Lancet* 1966;2:99-100.
22. Wahl MJ. Dental surgery in anticoagulated patients. *Arch Intern Med* 1998;158:1610-1616.
23. Kallio H, Paloheimo M, Maunuksela EL. Haemorrhage and risk factors associated with retrobulbar/peribulbar block: a prospective study in 1383 patients. *Br J Anaesth* 2000;85:708-711.
24. Gainey SP, Robertson DM, Fay W, et al. Ocular surgery on patients receiving long-term warfarin therapy. *Am J Ophthalmol* 1989;108:142-146.

25. Narendran N, Williamson TH. The effects of aspirin and warfarin therapy on haemorrhage in vitreoretinal surgery. *Acta Ophthalmol Scand* 2003;81:38-40.
26. Tuli SS, WuDunn D, Ciulla TA, et al. Delayed suprachoroidal hemorrhage after glaucoma filtration procedures. *Ophthalmology* 2001;108:1808-1811.
27. Arnold PN. Study of acute intraoperative suprachoroidal hemorrhage. *J Cataract Refract Surg* 1992;18:489-494.
28. McCormack P, Simcock PR, Tullo AB. Management of the anticoagulated patient for ophthalmic surgery. *Eye* 1993;7(Pt 6):749-750.
29. Morris A, Elder MJ. Warfarin therapy and cataract surgery. *Clin Experiment Ophthalmol* 2000;28:419-422.
30. Carter K, Miller KM. Phacoemulsification and lens implantation in patients treated with aspirin or warfarin. *J Cataract Refract Surg* 1998;24:1361-1366.
31. Katz J, Feldman MA, Bass EB, et al. Risks and benefits of anticoagulant and antiplatelet medication use before cataract surgery. *Ophthalmology* 2004;110:1784-1788.
32. Custer PL, Trinkhaus KM. Hemorrhagic complications of oculoplastic surgery. *Ophthalm Plast Reconstr Surg* 2002;18:409-415.
33. Hall DL, Stein WH Jr, Drummond JW, et al. Anticoagulants and cataract surgery. *Ophthalmic Surg* 1988;19:221-222.
34. McMahan LB. Anticoagulants and cataract surgery. *J Cataract Refract Surg* 1988;14:569-571.
35. Robinson GA, Mylander A. Warfarin and cataract extraction. *Br J Ophthalmol* 1989;73:702-703.
36. Bartley GB. Oculoplastic surgery in patients receiving warfarin: suggestions for management. *Ophthalm Plast Reconstr Surg* 1996;12:229-230.
37. Saitoh AK, Saitoh A, Taniguchi H, et al. Anticoagulation therapy and ocular surgery. *Ophthalmic Surg Lasers* 1998;29:909-915.
38. Jonas JB, Pakdaman B, Sauder G. Cataract surgery under systemic anticoagulant therapy with Coumadin. *Eur J Ophthalmol* 2006;16:30-32.
39. Flaxel CJ, Blach RK. Aspirin is a hazard for vitreoretinal surgery [letter]. *Br J Ophthalmol* 1996;80:486.
40. van Dijk KN, Plat AW, van Dijk AA, et al. Potential interaction between acenocoumarol and diclofenac, naproxen and ibuprofen and role of CYP2C9 genotype. *Thromb Haemost* 2004;91:95-101.
41. Chow DR, de Bustros S. Control of perioperative bleeding in vitreoretinal surgery. In: Ryan SJ, ed. *Retina*. 4th ed. Philadelphia: Elsevier; 2006:2451-2461.

PEER DISCUSSION

DR PAUL E TORNAMBE: 'If you prick us, do we not bleed?' (Shylock, Merchant of Venice, Act III Scene I). If Shylock needed vitreoretinal surgery and was taking warfarin at the time, Dr. Grand apparently would have said, "No, if we prick you, you probably will not bleed." Drs. Dayani and Grand provides us the largest series reported on this subject. Common sense suggests that stopping a drug that prevents blood from clotting before surgery should likely decrease the chances of intraoperative and postoperative bleeding. This paper provides good evidence that common sense does not always provide the correct answer. Sometimes the observation precedes the explanation. Perhaps the explanation lies in the incision size which is more like a puncture than a laceration. Perhaps the explanation lies in the vascularity of the tissue. Perhaps there is a difference between intravascular clotting, which prevents clots from forming on heart valves; and, extravascular clotting, which prevents a clot from plugging a vessel. Whatever the reason, this paper decisively shows that, if proper precautions are taken, it is not necessary to stop warfarin before vitreoretinal surgery.

The weakness of the study is its retrospective nature and relatively small sample size, but the remainder of the design is good. No patients were excluded, even those taking other drugs such as aspirin, non-steroidal anti-inflammatory drugs, or Plavix. There is adequate follow up, and grouping by INR strengthens the argument for the minor bleeding problems, which occurred in both adequately anti-coagulated and marginally anti-coagulated eyes.

Medicolegally, you're damned if you do and damned if you don't! The surgeon might be medicolegally exposed if the anticoagulants are stopped before surgery and the patient has an embolic event. On the other hand, there may be similar exposure if the drugs are not stopped and the patient experiences an expulsive hemorrhage.

It appears that warfarin does not have to be stopped before vitreoretinal surgery, but issues must be addressed preoperatively. There must be good communication with the patient's medical doctors. The patient must be responsible and the INR less than three. Blood pressure must be controlled, there should be no liver disease, and the intraoperative necessity of other anticoagulant medicines must be assessed.

There must be a surgical plan. If general anesthesia is not an option, a peribulbar injection with a blunt needle is advisable. If vessels are transected they should be cauterized either before or promptly after the dissection. If subretinal fluid drainage is necessary, it should be performed internally. To minimize the chances of choroidal detachment, hypotony should be avoided, and the vortex veins should not be compromised.

This paper brings important information to the vitreoretinal surgeon. Stopping warfarin may have life threatening implications. Although most of us consider the body an appendage of the eye, these circumstances mandate we consider the total patient's well being.

If you prick us, we may not bleed, but if you take a pound of flesh, we probably will!

DR MICHAEL H. GOLDBAUM.: One explanation for the benign outcome of the bleeding may be because you have a closed system that creates a tamponade as the bleeding causes the pressure to go up inside the eye. An eye more at risk may be one with a functioning bleb, which more approximates an open eye, where bleeding can expand without pressure tamponade.

DR ALLAN J. FLACH: It's a shame you didn't have data on Ginkgo Biloba and Vitamin E because that might be the explanation for the bleeding. It appeared in the sub-therapeutic group that there were an unusually large number of general anesthetics given. I wonder, since there were two hemorrhages there, could the hemorrhages have been related to the anesthesia or subsequent bucking or something specific to that approach to anesthesia?

DR DENNIS M. ROBERTSON: Ginkgo, garlic, ginseng, and ginger are four herbals pretty easy to remember because they all start with "g", but they all inhibit platelet aggregation. So, you might consider that in your patient history.

DR M. GILBERT GRAND : Dr Tornambe brings up the issue of relative risk. You have a relative risk of leaving your patient on anticoagulation, and taking the risk of anesthetic-related or surgically related hemorrhage, versus the risk of discontinuation of anticoagulation. Your decision depends greatly on the underlying disease process and the duration of that process. For instance, many patients who are anticoagulated have been on anticoagulants for many years, yet do not have a current reason for maintaining this anticoagulation. For example, they may have had a deep-vein thrombosis 15 years ago and warfarin has been maintained through this time. Or they may have had an episode of angina, for which they have been anticoagulated. There are some people for whom the risk of discontinuation is relatively minor. On the other hand, arterial embolisms are a much greater concern than are venous embolisms. Patients who have mechanical heart valves have a much greater risk of having a serious life-threatening condition occur following cessation of anticoagulation. The point that Dr. Tornambe made about communication with the patient's primary care doctor is a very valid one and should be the very first step.

The point of pricking or cutting was brought up. The reason I would have expected more bleeding was the fact that we are making three incisions through the so-called vascular tunic of the eye. At the time that we initially make those incisions, the globe is hypotonous so there is not a really good tamponade effect. But despite those incisions, we have not experienced bleeding in the course of vitrectomy.

The issue of the medical-legal aspects is a very critical one. There has been a recent symposium given by OMIC and among the cases that were presented was one in which the ophthalmologist was sued for administering the retrobulbar block in a patient on coumadin anticoagulation. There was a judgment in favor of the plaintiff in that case. The older literature indicates that anticoagulation should be modified or discontinued prior to embarking on ocular surgery. But a more recent appraisal of the literature shows that certainly cataract surgery can be done safely despite anticoagulation. Our study has shown that the risk of bleeding during vitreoretinal surgery, while not zero, is smaller than one might have anticipated. Thus it is a reasonable option, made with the patient's internist and the patient, to embark on a course of maintaining coagulation.

The reasons for the use of Avastin continue to expand. Like Dr. Tornambe, we have used Avastin in pre-vitrectomy treatment of diabetics with severely aggressive vascular proliferation, both those who have iris neovascularization as well as those with fibrovascular proliferation in the retina. Like Dr. Tornambe has shown, within a matter of three or four days, the vascularity regresses dramatically. . I think this does make for safer intraocular surgery.

As far as the tamponade effect that Dr. Goldbaum raised, there is some tamponade as we do our cases, sometimes with pressures in the 30s. Tamponade may be the reason that we can do intraocular injections, such as Kenalog or Avastin, without much risk of bleeding. We have not specifically looked at needle perforation into the globe for these reasons in patients who are anticoagulated, but I suspect the risk of bleeding is small since there is a period of ocular hypertension related to the immediate injection.

As far as use of nutritional supplements, I do not have that information.