

# VASCULAR PERFUSION OF CHOROIDAL MELANOMA BY 3.0 TESLA MAGNETIC RESONANCE IMAGING

---

BY Bruce M. Buerk MD, **Jose S. Pulido MD MS**,\* Ignacio Chiong, Robert Folberg MD, Deepak P. Edward MD, Mark T. Duffy MD PhD, AND Keith R. Thulborn MD PhD

## ABSTRACT

*Purpose:* Because signal-to-noise performance improves with increased magnetic field strength, the quality of magnetic resonance images is greater at 3.0 tesla (T) than at 1.5 T. Because of the longer T1 values at higher field strength, intravenously administered magnetic resonance contrast agents provide improved T1 enhancement at 3.0 T. We have used these factors to obtain high-quality contrast-enhanced imaging of small intraocular lesions using a standard head radiofrequency volume coil. Specifically, we have examined lesion size and magnitude of maximum contrast enhancement in a series of intraocular melanomas before and during therapy.

*Methods:* Eighteen patients with intraocular masses were examined by 3.0 T magnetic resonance imaging (MRI) including intravenous contrast enhancement. Precontrast images were acquired through the orbits followed by sequential post-contrast images at 1-minute intervals for 5 minutes. The magnitude of contrast enhancement of the lesion, extraocular muscles, and brain parenchyma was measured as a percentage increase in magnetic resonance signal over the pre-enhancement signal intensity.

*Results:* Lesions demonstrated different levels of enhancement ranging up to 130%. Three patterns of enhancement—0% to 20%, 20% to 50%, and >50%—were identified. Brain parenchyma, benign lesions, and responsive tumors following brachytherapy with <sup>125</sup>I demonstrated enhancement of less than 20%. Four choroidal melanomas showed intermediate (20% to 50%) levels of enhancement. Four malignant lesions (three melanomas, one metastatic tumor), as well as the extraocular muscles, showed strong, rapid enhancement (>50%). Four patients who had MRI studies before and following plaque brachytherapy ultimately demonstrated a decline in the contrast enhancement following treatment.

*Conclusions:* Contrast enhancement of intraocular lesions measured by 3.0 T MRI demonstrates different patterns of enhancement that may be useful for indicating the degree of malignancy and in monitoring response to therapy.

*Trans Am Ophthalmol Soc* 2004;102:209-217

## INTRODUCTION

---

The evaluation of choroidal melanomas is based on the clinical findings by ophthalmoscopy and ultrasonography. Greater than 99% of choroidal melanomas can be correctly diagnosed by experienced observers using these methods.<sup>1</sup> Ancillary testing, such as fluorescein angiography, computed tomography, and magnetic resonance imaging (MRI), is used primarily to differentiate types of

mass lesions and to define their extent.

Although most clinical scanners are still 1.5 tesla (T), recently introduced 3.0 T scanners are rapidly proving that the higher signal-to-noise performance of higher magnetic field improves image spatial and temporal resolution. Dedicated MRI studies of the orbits are now possible with the standard head coil rather than having to resort to specialized surface coils. The longer longitudinal relaxation times (T1) at higher field make the same dose of intravenous contrast agent more effective, thereby enhancing T1-weighted images that can be acquired rapidly through the orbits. Despite the small size of intraocular lesions, sequential images can be obtained following contrast administration to allow the maximum enhancement to be determined accurately. This study was undertaken to evaluate the contrast enhancement characteristics of 18 intraocular mass lesions (14 choroidal melanomas, one metastatic lesion, two subretinal hemorrhages, and a choroidal nevus).

From the Department of Ophthalmology and Visual Sciences (Drs Buerk, Pulido, Folberg, Edward, and Duffy), the Center for Magnetic Resonance Research (Mr Chiong, Dr Thulborn), and the Department of Pathology and Laboratory Sciences (Dr Folberg), University of Illinois at Chicago, Chicago, Illinois. Supported in part by grant EY10457 and Core grant EY01792 from the National Eye Institute, National Institutes of Health, as well as an unrestricted grant from Research to Prevent Blindness, Inc, New York, New York.

\*Presenter.

Bold type indicates **AOA** member.

## METHODS

We studied 18 patients from June 2000 to September 2002 who presented to the Retina Service at the University of Illinois at Chicago with intraocular masses. All patients received a complete ophthalmic examination including ultrasonography. Fluorescein angiography was performed on six of 18 patients. All patients underwent a complete metastatic evaluation by the internal medicine service.

This retrospective study of ocular MRI examinations was performed under the approval of the institutional review board. Magnetic resonance imaging with intravenous contrast enhancement was performed on a 3.0 T whole-body scanner (Signa VHi 3T; General Electric Medical Systems, Milwaukee, Wisconsin).<sup>1</sup> Sagittal T1-weighted FLAIR (fluid attenuated inversion recovery) images (TR = 2,613 ms, TE = 16 ms, FOV = 24 cm<sup>2</sup>, acquisition matrix = 512 × 192, image thickness = 5 mm) through the head were used for graphic prescription of axial T2-weighted fast-spin echo images (TR = 5,000 ms, TE = 102 ms, FOV = 15 cm<sup>2</sup>, acquisition matrix = 416 × 416, image thickness = 1.5 mm, gap = 0.5 mm) through the orbits. Precontrast axial T1-weighted spin echo images (TR = 400 ms, TE = 19 ms, FOV = 14 cm<sup>2</sup>, acquisition matrix = 416 × 160, image thickness = 3 mm, gap = 0.5 mm) were then obtained through the ocular lesion. For lesions placed in the superior or inferior regions of the globe, images were obtained in the coronal plane for improved visualization.

Following administration of gadolinium–diethylenetriamine pentaacetic acid (DTPA) contrast (Omniscan, 0.1 mmol/kg) via an antecubital vein, 5 volumes of same T1-weighted spin echo images were acquired through the globes at 1-minute intervals for 5 minutes. The time-dependent enhancement patterns were obtained using the average signal intensity from five separate regions of interest placed over each of three locations: the ocular lesion, the brain gray matter, and the extraocular muscles, as a function of time (Functools; General Electric Medical Systems, Milwaukee, Wisconsin). The average and standard deviation of the maximum enhancement for each region were calculated as the percentage difference between the preenhancement and maximum postenhancement signal intensities divided by the preenhancement signal intensity for each tissue on the T1-weighted images (Microsoft Excel; Microsoft Corporation, Everett, Washington). The gray matter of the brain served as a measure of signal intensity stability over time, because no enhancement should occur away from blood vessels when the blood-brain barrier is intact. The muscle served as a measure of enhancement expected for normally perfused tissue.

Lesion size was documented from the contrast-

enhanced T1-weighted images as the longest baseline dimension in the axial or coronal plane and the greatest thickness of the lesion from the sclera into the vitreous.

Four eyes (patients 10, 15, 17, and 18) with large uveal melanomas were treated by enucleation. Each eye was fixed in 10% neutral buffered formalin and stained with hematoxylin-eosin and the periodic acid–Schiff stain without hematoxylin counterstaining to demonstrate vasculogenic mimicry looping patterns.<sup>2</sup>

## RESULTS

Table 1 categorizes the patients' clinical information (including age, race, sex), magnetic resonance characteristics of the lesion, magnetic resonance contrast enhancement characteristics, histopathologic findings, and presence or absence of microcirculatory networks. The shape and location of these lesions on MRI correlated with the clinical examination. All of the uveal lesions were well visualized on both T1-weighted images (T1WI) and T2-weighted images (T2WI). Fourteen of the lesions suspected of being choroidal melanomas were found to be hyperintense relative to vitreous on T1WI and hypointense relative to vitreous on T2WI (Figure 1). In contrast, the lesions from age-related macular degeneration and the nevus were dark on T1-weighted images. The size as measured by ultrasonography correlated well with the size measured on MRI.

The contrast enhancement of these lesions demonstrated three patterns of enhancement: <25%, 25% to 50%, and >50% (Figure 2). Benign lesions or some lesions following plaque brachytherapy with <sup>125</sup>I demonstrated enhancement of less than 20%. One melanoma lesion (patient 1) did not enhance, but this patient had recently undergone chemotherapy for a primary lung adenocarcinoma, presumably also treating the coincidental ocular lesion. There were four choroidal melanomas with an intermediate (25% to 50%) degree of enhancement. Eight lesions (seven melanomas, one metastatic tumor) showed strong, rapid enhancement (>50%). The four patients (patients 5, 6, 8, and 17) who had contrast enhancement studies following plaque brachytherapy (Figure 3) showed declines in contrast enhancement following treatment (range, 3 to 17 months following treatment). Two of the patients (patients 5 and 8) initially demonstrated a strong increase in perfusion following brachytherapy, followed by a decline in contrast enhancement.

Four globes (from patients 10, 15, 17, and 18) were enucleated and examined by histopathology (Table 1). Three of the four tumors demonstrated spindle B melanoma cells. One tumor was composed of mixed epithelioid and spindle B tumor cells. No microcirculatory loops or networks were identified in any of the specimens.

TABLE 1. DEMOGRAPHIC DATA AND MAGNETIC RESONANCE IMAGING AND HISTOLOGIC RESULTS FOR 18 PATIENTS WITH INTRAOCULAR MASSES

PATIENT NO.	AGE	SEX	DIAGNOSIS	T1WI	T2WI	% ENHANCEMENT	PATH	MICRO
1	73	F	CM	Bright	Dark	0°	–	NA
2	20	M	PNET	Isointense	Dark	65	–	NA
3	26	M	CM	Bright	Dark	75	–	NA
4	62	F	CM	Bright	Dark	125	–	NA
5	63	M	CM	Bright	Dark	58	–	NA
6	43	M	CM	Bright	Dark	58	–	NA
7	58	M	CM	Bright	Dark	58	–	NA
8	73	M	CM	Bright	Dark	50	–	NA
9	78	M	ARMD	Dark	Dark	5	–	NA
10	75	M	CM	Bright	Dark	57	Spindle B	None
11	46	M	CM	Bright	Dark	19	–	NA
12	59	F	ARMD	Dark	Dark	17	–	NA
13	63	F	Choroidal nevus	Dark	Dark	19	–	NA
14	83	F	CM	Bright	Dark	25	–	NA
15	84	F	CM	Bright	Dark	18	Spindle B	None
16	63	F	CM	Bright	Dark	36	–	
17	67	F	CM	Bright	Dark	75	Spindle B	None†
18	31	M	CM	Bright	Dark	35	Mixed‡	None

ARMD, age-related macular degeneration; CM, choroidal melanoma; Micro, microcirculation networks; NA, not applicable; Path, pathology; PNET, primary neuroendocrine tumor; T1WI, T1-weighted images; T2WI, T2-weighted images. Dashed line = no pathology was obtained.

\*Patient had received recent chemotherapy for primary lung carcinoma.

†Enucleation 3 months following plaque brachytherapy.

‡Mixed epithelioid/spindle B tumor.

## DISCUSSION

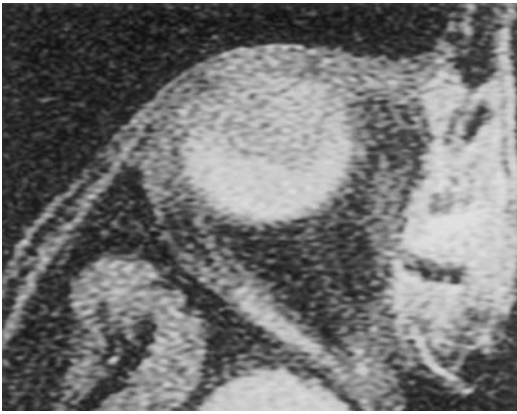Although ophthalmoscopy and ultrasonography remain the primary modalities for evaluating intraocular masses,<sup>1</sup> MRI can provide additional information on difficult cases regarding diagnosis and evaluation of extraocular extension.<sup>3-10</sup> Some investigators have noted decreased effectiveness of MRI in imaging amelanotic lesions.<sup>1-9</sup>

Choroidal melanomas are hyperintense on T1WI and hypointense on T2WI relative to the vitreous humor. These findings are due to the shortened T1 and T2 relaxation times of choroidal melanomas compared with surrounding structures. The shortened relaxation times are due to the paramagnetic properties of melanin.<sup>1-9</sup> Melanin has been shown to produce stable free radicals, which can cause proton relaxation enhancement, thereby shortening both T1 and T2 time values.<sup>6-8</sup> In contrast, most other ocular tumors and tumors elsewhere in the body generally have prolonged T1 and T2 times.<sup>6-8</sup> The addition of gadolinium-DTPA has been found to enhance tumor delineation by shortening the T1 relaxation time to produce increased signal intensity on T1WI.<sup>4,9</sup> This effect

is further enhanced at 3.0 T compared with 1.5 T.

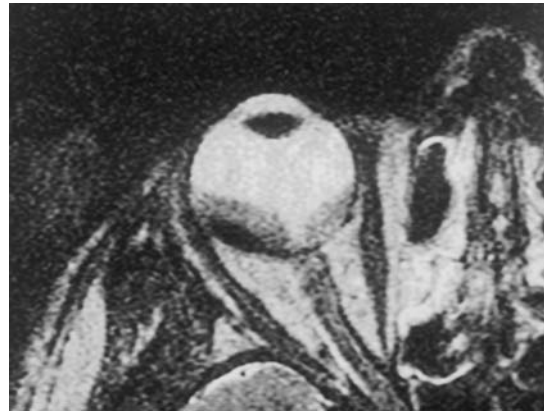This study was undertaken to evaluate whether the degree of intravenous contrast enhancement of intraocular masses, as demonstrated on a 3.0 T scanner using the standard head coil, could be used to distinguish benign from malignant lesions and to follow response of malignancies to brachytherapy. The enhancement findings of the lesions were compared with muscle, which demonstrates strong, rapid perfusion, and brain, which does not normally enhance (Figure 2). There were three patterns of perfusion noted: 0% to 25%, 25% to 50%, and >50%. Among the 0% to 25% group, the lesions were benign or previously treated choroidal melanomas. Although one patient (patient 1) had an active choroidal melanoma, she had received chemotherapy for a primary lung adenocarcinoma, which may have altered the enhancement of the choroidal melanoma. Four tumors demonstrated intermediate (25% to 50%) patterns of perfusion, and eight lesions demonstrated strong, rapid uptake of contrast (>50%), consistent with metastatic or malignant lesions.

The effect of plaque brachytherapy on degree of enhancement was evaluated. All tumors treated with



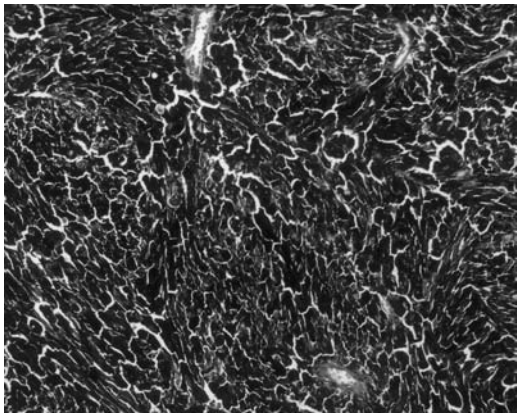
**FIGURE 1A**

T1-weighted image of orbit demonstrating hyperintense mass relative to vitreous of right eye. This choroidal melanoma has an associated retinal detachment that appears slightly less hyperintense.



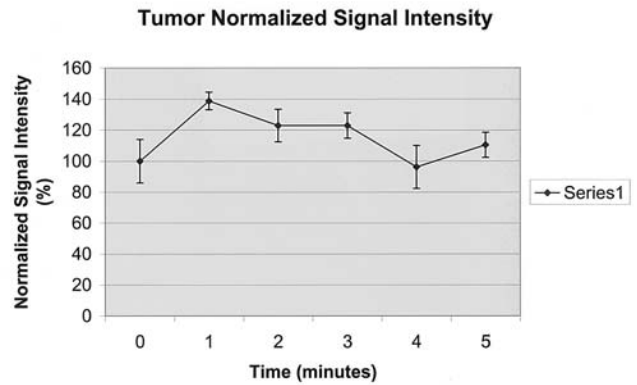
**FIGURE 1B**

T2-weighted image of orbit of same case shown in 1A, demonstrating hypointense mass relative to vitreous of right eye. Note that in the T2-weighted image, the choroidal melanoma is seen as more hypointense than the overlying retinal detachment and the vitreous cavity, which has the most hyperintense signal in the eye.



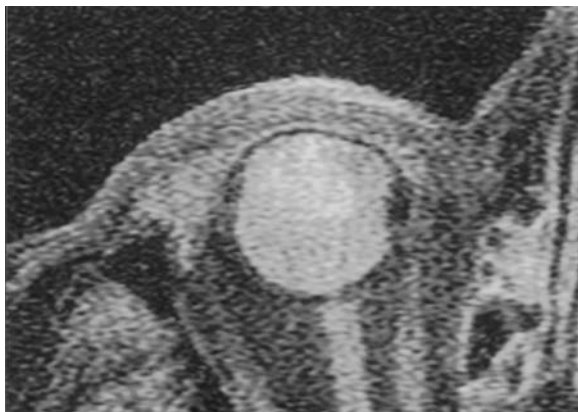**FIGURE 1C**

Histopathology of the same case shown in 1A, demonstrating an array of spindle B cells and epithelioid cells. No vascular looping patterns were seen by periodic acid-Schiff staining.



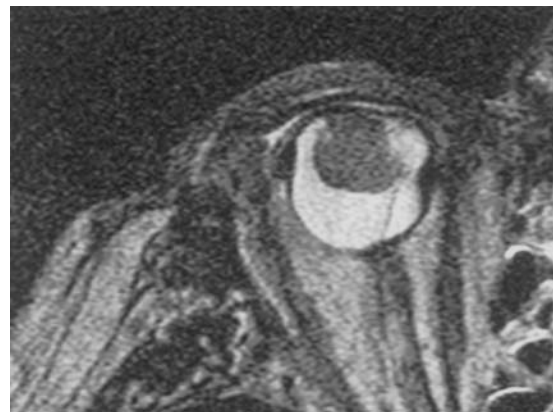**FIGURE 1D**

Plot of the change in vascular enhancement of the same choroidal melanoma shown in 1A over time. Note that there is a maximum enhancement of 40% over the initial level.



**FIGURE 1E**

T1-weighted image of the orbit of a large ciliary body melanoma. Note the shrunken right eye with the enhancing mass extending from the wall of the globe into the anterior chamber.



**FIGURE 1F**

T2-weighted image demonstrating the hypointensity of the large ciliary body melanoma shown in 1E, extending into the anterior chamber. The vitreous is hyperintense compared with the melanoma.

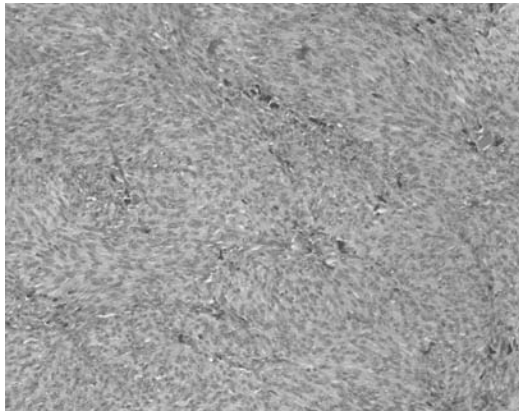


FIGURE 1G

Photomicrograph of a histologic section of same melanoma seen in 1E, showing that the lesion is composed of predominantly spindle B cells. No vascular loops were seen with periodic acid-Schiff staining.

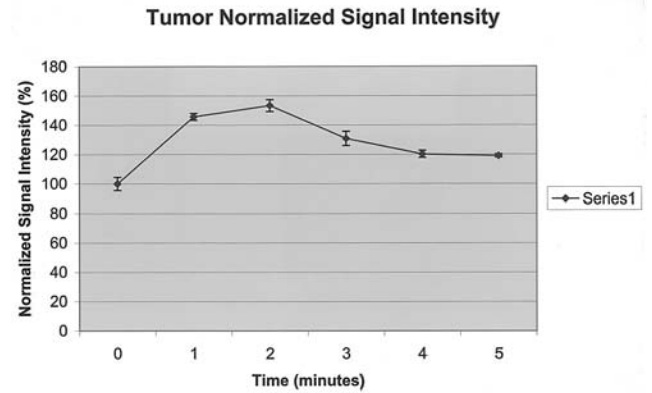


FIGURE 1H

Plot of vascular perfusion of the same ciliary body choroidal melanoma seen in 1E, demonstrating a maximum of 55% enhancement. Note also the slow downward return of the enhancement toward baseline.

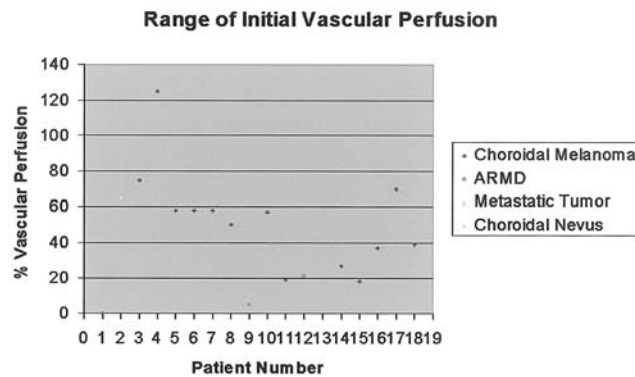


FIGURE 2

Scatter plot demonstrating range of maximum vascular enhancement by 3 tesla magnetic resonance imaging of 18 patients with intraocular masses prior to treatment. The key shows the probable diagnosis of each intraocular lesion.

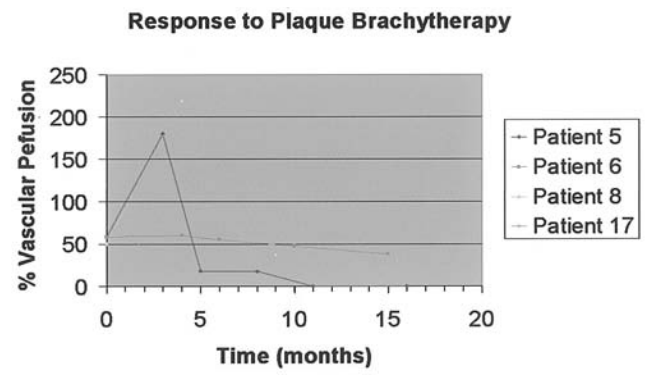


FIGURE 3

Graph demonstrating the time course of the response of the choroidal melanomas' vascular enhancement to plaque brachytherapy with <sup>125</sup>I in the four cases that underwent brachytherapy. Note the increase in enhancement in two cases in the early time course followed by a diminution from the baseline levels.

plaque brachytherapy demonstrated a decline in the percentage of enhancement. Interestingly, two of the tumors initially had an increase in enhancement after treatment followed by a subsequent decline in enhancement. We hypothesize that radiation damage to the tumor vasculature initially enhanced leakage of contrast material from the tumor circulation but later decreased as vessels underwent thrombosis. Prior studies demonstrated thickening, thrombosis, and blood vessel damage<sup>11-14</sup> following radiation treatment to choroidal melanomas.

Four tumors were enucleated and evaluated by histopathology. Three of the tumors were composed of spindle B cells, and one tumor was composed of mixed spindle B and epithelioid tumor cells. We examined the tumor for the presence of microcirculatory loops and networks. The presence of these networks has been correlated with an increased risk of metastatic disease.<sup>15-19</sup> No tumors had microcirculatory loops or networks. With a larger cohort of tumors, future areas of investigation may

include associations between contrast enhancement of choroidal melanomas and microcirculatory patterns.

Other imaging modalities for imaging the vascular pattern of choroidal melanomas are currently being investigated. Indocyanine green (ICG) angiography is a technique utilizing the ability of long near-infrared wavelength to penetrate the retinal pigment epithelium.<sup>20</sup> The ICG is highly protein-bound and therefore remains predominantly within the choroidal vessels. Confocal ICG scanning laser ophthalmoscopy has improved resolution to view vessels to 20  $\mu$ m.<sup>21-23</sup> Investigators have used the confocal ICG scanning laser to image choroidal melanoma microcirculation patterns that have been correlated with increased risk of metastatic death.<sup>15-19</sup> These vessels have been shown to regress after plaque brachytherapy,<sup>22,23</sup> and their presence in small melanocytic tumors is predictive for future growth.<sup>23</sup>

Doppler ultrasound technology has also been used to demonstrate the vascular perfusion of choroidal tumors.<sup>24-30</sup>

Guthoff and associates<sup>25,28</sup> demonstrated blood flow within choroidal melanomas and a decrease in Doppler shift following plaque brachytherapy. They felt that persistent circulation in areas of tumor following plaque brachytherapy likely represented areas of tumor viability.<sup>25,28</sup> Lieb and colleagues<sup>26</sup> demonstrated no flow on Doppler ultrasound in nonmalignant lesions. They also showed lower blood flow in choroidal melanomas after treatment with plaque brachytherapy. Silverman and associates<sup>30,31</sup> were able to differentiate choroidal melanomas into high- and low-risk groups by correlating ultrasound spectrum analysis with histopathologic presence or absence of extravascular matrix patterns on the basis of power spectrum analysis of raw radiofrequency ultrasound data. This technique detects patterning within tumors without detecting blood flow.

None of our patients who underwent enucleation and whose tumors were available for histopathologic study (cases 10, 15, 17, and 18) have experienced metastatic disease, but the follow-up interval is short. None of these patients showed evidence of extravascular matrix patterning in their tumors, but three of these tumors (in patients 10, 17, and 18) were recorded as having "high % enhancement" by 3.0 T MRI imaging. These early data suggest that 3.0 T MRI may be measuring effects related to larger vessels and not from vasculogenic mimicry patterning.

In summary, contrast dynamic imaging has been shown to be of value at 1.5 T to evaluate the vascularity of lesions, and with even better spatial and temporal resolution at 3 T, the ability to evaluate internal tumor characteristics has improved further.<sup>32-40</sup> This small retrospective study demonstrates that 3.0 T MRI detects different enhancement patterns for different intraocular masses. There seem to be three patterns of enhancement: 0% to 25%, 25% to 50%, and >50%. Benign or treated lesions demonstrate perfusion under 25%. Malignant lesions seem to demonstrate enhancement greater than 25%, with most choroidal melanomas demonstrating strong enhancement (>50%), suggesting a malignant process. Following plaque brachytherapy, the enhancement may initially increase, but then declines without any increase and often with a decrease in lesion size. Further studies are needed to ascertain if this contrast enhancement pattern can be used to monitor therapy for ocular malignancies.

## REFERENCES

- Char DH. Diagnosis of choroidal melanoma. In: Ryan SJ, ed. *Retina*. 3rd ed. St Louis: Mosby; 2000:673-686.
- Folberg R, Rummelt V, Parys-Van Ginderdeuren R, et al. The prognostic value of tumor blood vessel morphology in primary uveal melanoma. *Ophthalmology* 1993;100:1389-1398.
- Raymond WR, Char DH, Norman D, et al. Magnetic resonance imaging evaluation of uveal tumors. *Am J Ophthalmol* 1991;111:633-641.
- DePotter P, Flanders AE, Shields JA, et al. Magnetic resonance imaging of intraocular tumors. *Int Ophthalmol Clin* 1993;33:37-45.
- Chambers RB, Davidorf FH, McAdoo JF, et al. Magnetic resonance imaging of uveal melanomas. *Arch Ophthalmol* 1987;105:917-921.
- Mafee MF, Peyman GA, Peace JH, et al. Magnetic resonance imaging in the evaluation and differentiation of uveal melanoma. *Ophthalmology* 1987;94:341-348.
- Mafee MF, Inoue Y, Mafee RF. Ocular and orbital imaging. *Head Neck Imaging* 1996;6:291-318.
- Wycliffe ND, Mafee MF. Magnetic resonance imaging in ocular pathology. *Top Magn Reson Imaging* 1999;10:384-400.
- Bond JB, Haik BG, Mihara F, et al. Magnetic resonance imaging of choroidal melanomas with and without gadolinium contrast enhancement. *Ophthalmology* 1991;98:459-466.
- McCaffey S, Simon EM, Fischbein NJ, et al. Three dimensional magnetic resonance imaging of ocular and orbital malignancies. *Arch Ophthalmol* 2002;120:747-754.
- Klaus H, Lommatzsch PK, Fuchs U. Histopathology studies in human malignant melanomas of the choroid after unsuccessful treatment with <sup>106</sup>Ru/<sup>106</sup>Rh ophthalmic applicators. *Graefes Arch Clin Exp Ophthalmol* 1991;29:480-486.
- Saornil MA, Egan KM, Gragoudas ES, et al. Histopathology of proton beam-irradiated vs enucleated uveal melanomas. *Arch Ophthalmol* 1992;110:1112-1118.
- Saornil MA, Sisher MR, Cambell RJ. Histopathologic study of eyes after I<sup>125</sup> episcleral plaque for uveal melanoma. *Arch Ophthalmol* 1997;115:1395-1400.
- Crawford JB, Char DH. Histopathology of uveal melanoma treated with charged particle radiation. *Ophthalmology* 1987;94:639-643.
- Folberg R, Rummelt V, Ginderdeuren RP, et al. The prognostic value of tumor blood vessel morphology in primary uveal melanoma. *Ophthalmology* 1993;100:1389-1398.
- Rummelt V, Folberg R, Rummelt C, et al. Microcirculation architecture of melanocytic nevi and malignant melanomas of the ciliary body and choroid. *Ophthalmology* 1994;101:718-727.
- Folberg R, Mehaffey M, Gardner L. The microcirculation of choroidal and ciliary body melanoma. *Eye* 1997;11:227-238.
- Rummelt V, Folberg R, Woosib R, et al. Relationship between microcirculation architecture and the aggressive behavior of ciliary body melanoma. *Ophthalmology* 1995;102:844-851.
- Folberg R, Chen, Boldt HC, et al. Microcirculation patterns other than loops and networks in choroidal and ciliary body melanomas. *Ophthalmology* 2001;108:996-1001.
- Shields CL, Shields JA, DePotter P. Patterns of indocyanine green videoangiography of choroidal tumors. *Br J Ophthalmol* 1995;79:237-245.
- Mueller AJ, Bartsch DU, Mehaffey MG, et al. Imaging the microvasculature of choroidal melanomas with confocal indocyanine green scanning laser ophthalmoscopy. *Arch Ophthalmol* 1998;116:31-39.

22. Mueller AJ, Bartsch DU, Schaller U, et al. Imaging the microcirculation of untreated and treated human choroidal melanomas. *Int Ophthalmol* 2001;23:385-393.
23. Schaller UC, Mueller AJ, Bartsch DU, et al. Choroidal melanoma microcirculation with confocal indocyanine green angiography before and 1 year after radiation brachytherapy. *Retina* 2000;20:627-632.
24. Mueller AJ, Freeman WR, Schaller UC, et al. Complex microcirculation patterns detected by confocal indocyanine green angiography predict time to growth of small choroidal tumors. *Ophthalmology* 2002;109:2207-2214.
25. Guthoff RF, Berger RW, Winkler P. Doppler ultrasonography of malignant melanomas of the uvea. *Arch Ophthalmol* 1991;109:537-541.
26. Lieb WE, Shields JA, Cohen SM. Color Doppler imaging in the management of intraocular tumors. *Ophthalmology* 1990;97:1660-1664.
27. Wolff-Kormann BA, Kormann BA, Riedel KG, et al. Doppler imaging in untreated and irradiated choroidal melanoma. *Invest Ophthalmol Vis Sci* 1992;33:1928-1933.
28. Guthoff R, Winkler P, Helmke K, et al. Diagnosis and treatment control of choroidal melanomas: the role of B-scan and Doppler technique. *Acta Ophthalmol* 1992;204(suppl):59-61.
29. Regan S, Egan KM, Hart L, et al. Color Doppler imaging of untreated and irradiated choroidal melanomas. *Eur J Ophthalmol* 2001;11:150-155.
30. Silverman RH, Folberg R, Boldt HC. Correlation of ultrasound parameter imaging with microcirculatory patterns in uveal melanomas. *Ultrasound Med Biol* 1997;23:573-581.
31. Coleman DJ, Silverman RH, Rondeau MJ, et al. Noninvasive in vivo detection of prognostic indicators for high-risk uveal melanoma: ultrasound parameter imaging. *Ophthalmology* 2004;111:558-564.
32. Thulborn KR. Clinical rationale for very high field (3.0 Tesla) functional MR imaging. *Top Magn Reson Imaging* 1999;10:37-50.
33. Kuhl CK, Mielcarek P, Klaschick S, et al. Dynamic breast MR imaging: Are signal intensity time course data useful for differential diagnosis of enhancing lesions? *Radiology* 1999;211:101-110.
34. Gilles R, Guinebretiere JM, Lucidarme O, et al. Nonpalpable breast tumors: diagnosis with contrast-enhanced subtraction dynamic MR imaging. *Radiology* 1994;191:625-631.
35. Boetes C, Barentsz JO, Mus RD, et al. MR characterization of suspicious breast lesions with enhanced TurboFLASH subtraction technique. *Radiology* 1994;193:777-781.
36. Yang S, Law M, Zagzag D, et al. Dynamic contrast-enhanced perfusion MR imaging measurements of endothelial permeability: differentiation between atypical and typical meningiomas. *Am J Neuroradiol* 2003;24:1554-1559.
37. Berger MS. Perfusion MR and the evaluation of meningiomas: Is it important surgically? *Am J Neuroradiol* 2003;24:1499-1500.
38. Molls M, Feldmann J, Sievers K. Clinical investigations on blood perfusion in human malignancies of the pelvis and abdomen: significance for tumor therapy. In: Steiner R, Weisz PB, Langer R, eds. *Angiogenesis: Key Principles-Science-Technology-Medicine*. Basel, Switzerland: Birkhauser Verlag; 1992:368-372.
39. Feldmann HJ, Sievers K, Fuller J, et al. Evaluation of tumor blood perfusion by dynamic MRI and CT in patients undergoing thermotherapy. *Eur J Radiol* 1993;16:224-229.
40. Degani H, Chetrit-Dadiani M, Bogin L, et al. Magnetic resonance imaging of tumor vasculature. *Thromb Haemost* 2003;89:25-33.

## DISCUSSION

---

DR JAMES J. AUGSBURGER. The authors of this report ostensibly determined the vascular perfusion of choroidal melanomas and a number of other lesions using 3 Tesla magnetic resonance imaging. Regrettably, they really didn't do what they said they did. All they did was determine the contrast enhancement of evaluated lesions. Too few lesions were evaluated to allow any meaningful conclusion about the relative enhancement patterns of choroidal melanomas and alternative tumors. The authors reported post-imaging survival data on only a few of their patients, so one cannot make any scientifically valid statement about the prognostic value of the obtained information.

Rather than dwell on specific shortcomings of this paper, I'd like to ask an important ethical question raised by this study. My question is "Who should pay for investigational clinical studies?" In any exploratory clinical research study such as this one, I believe that the cost of the studies being evaluated should be borne by the researchers or their grants and not by the patients or their insurers. The authors of this report will no doubt counter that MRI with contrast is not in and of itself an experimental technique. They will undoubtedly also assert that MRI's of the orbits and brain are performed frequently in many centers for other indications and even sometimes for evaluation of intraocular mass lesions. I agree completely with both of these assertions. However, MRI's of the orbits and brain or any other clinical studies (including fluorescein angiograms, ICG angiograms, OCT's, corneal topographic maps, etc.) obtained primarily for the purpose of producing descriptive clinical data about the spectrum of findings in lesions of different types but which provide no information that changes subsequent patient management are clearly research studies. As such, they should not be billed to the patients or their insurers.

DR GERHARD W. CIBIS. I would like to address the issue raised of billing a patient for a test that may not in any way

influence the treatment or outcome of that individual. Having run an electrophysiology lab where, frequently, the answers from my electroretinograms did nothing for the treatment of the patient, I think the information gathered in that way and paid for by the insurance companies was nonetheless extremely valuable.

DR JOSE S. PULIDO. I would like to thank Dr Augsburger for having sent to me a critique of an earlier manuscript. Some of his criticisms have been addressed in the submitted manuscript and it has helped to improve this groundbreaking study. In regards to the specific MR imaging methods, these have been added in this manuscript. As for the relationship between enhancement and perfusion, they are strongly associated and the MR literature oscillates between the two. For instance, Molls et al state, "The gadolinium-induced enhancement of signal intensity versus noise in the early phase after bolus injection is a reliable parameter for the perfusion in the regions of interest.... Thus the pre-therapeutic investigation of blood flow (dynamic CT, MRI, Positron emission tomography) can contribute to a more individual planning of treatment (decision for or against hyperthermia in addition to radiotherapy or chemotherapy)."<sup>1</sup>

Furman-Haran and her colleagues state, "The kinetics and extent of signal enhancement are related to changes in the concentration of the contrast agent... Physiological models used to analyze contrast-enhanced images and obtain perfusion parameters of tracer kinetics were based on the work of... Problem is good high temporal and concomitant spatial resolution while at the same time maintaining a sufficient signal-to-noise ratio."<sup>2</sup>

Let me address the issue of the use of MR imaging. First, we had IRB approval. Secondly, one of the great strengths of ophthalmology is our specialization to our small area of the body. On the other hand, this can also turn into a weakness because we have to resist the urge to be insular and provincial when it comes to advances elsewhere in the body. I believe that Dr Augsburger's criticisms come from not knowing the extensive literature regarding the clinical use of MRI for evaluation of vascularity for many other forms of tumors throughout the body and the brain.

Last year, Dr Paul Lauterbur from the University of Illinois won a Nobel Prize for his pioneering work in magnetic resonance imaging.<sup>3</sup> The University of Illinois has always been at the forefront in MR imaging and the work from Dr Mahmood Mafee has set the bar for the use of MR in orbital diseases.<sup>4,7</sup> Dr Augsburger's misperceptions about the value of MR probably arose from the early studies using the 0.5 Tesla machines and the early 1.5 Tesla machines where the spatial resolution was poor.<sup>5</sup> By the late 90s the resolution was good enough that MR

imaging at least rivaled ultrasound for detection of extraocular extension.<sup>9-11</sup>

During the same time period, the temporal resolution was being exploited by others to look at the vascularity of tumors in the breast, the brain, and other areas in the body.<sup>1,2,12-15</sup> Indeed, Kuhl and colleagues wrote, "The diagnostic value of the early-phase enhancement rate criterion has been established by the findings of several recent studies... In practice, evaluation of lesion time course kinetics has already had considerable effect on the management of lesions in breast MR imaging."<sup>12</sup>

Furman-Haran and colleagues state, "In contrast to histological assessment, contrast-enhanced magnetic resonance imaging, which is increasingly employed in the clinic, is a highly sensitive, noninvasive technique for detecting and diagnosing the nature of breast lesions. Moreover, it has great value as a quantitative tool for mapping the unique properties of tumor vasculature."<sup>2</sup>

Another quotation showing the value of perfusion imaging was from Degani and colleagues who wrote, "It can monitor alterations in vascular parameters during tumor development, in response to treatment and during metastatic spread. The use of this methodology in the clinic has proven to be a highly efficient technique of the diagnosis and prognosis of malignant lesions."<sup>15</sup>

With the advent of 3Tesla imaging, which parenthetically, was championed by one of my co-authors, high spatial as well as temporal resolution is possible and this is becoming the unit of choice throughout the United States. We are presently working on a 9.4 Tesla machine.

Finally, considering that vascularity is a separate prognostic indicator and therapeutic indicator elsewhere in body and that work from another of my co-authors, Dr. Folberg, as referenced in the manuscript, shows that it is also important for uveal melanomas and we recommend the use of the special ultrasound machine championed by Dr Coleman or the 3Tesla imaging that we are using to monitor patients.

## REFERENCES

1. Molls M, Feldmann J, Sievers K. Clinical investigations on blood perfusion in human malignancies of the pelvis and abdomen: significance for tumor therapy. In: Steiner R, Weisz PB, Langer R, editors. *Angiogenesis: Key principles-Science-Technology-Medicine* Basel: Birkhauser Verlag; 1992:368-372.
2. Furman-Haran E, Kelcz F, Degani H. Magnetic resonance imaging of breast cancer angiogenesis: A review. *J Exp Clin Cancer Res* 2002;21:47-54.
3. Lauterbur PC. Image formation by induced local interactions: examples employing nuclear magnetic resonance. *Nature* 1973;242:190-191.
4. Mafee MF, Peyman GA. Retinal and choroidal detachments:



- Role of magnetic resonance imaging and computed tomography. *Radiol Clin North Am* 1987;25:487-507.
5. Mafee MF, Peyman GA, Grisolano JE, et al. Malignant uveal melanoma and simulating lesions: MR imaging evaluation. *Radiology* 1986;160:773-780.
  6. Mafee MF, Puklin J, Barany M, et al. MRI and in vivo proton spectroscopy of the lesions of the globe. *Semin Ultrasound CT MR* 1988;9:428-442.
  7. Mafee MF, Peyman GA, Peace JH, et al. Magnetic resonance imaging in the evaluation and differentiation of uveal melanoma. *Ophthalmology* 1987;94:341-348.
  8. Wilms G, Marchal G, Van Fraeyenhoven L, et al. Shortcomings and pitfalls of ocular MRI. *Neuroradiology* 1991;33:320-325.
  9. Weber AL, Mafee MF. Evaluation of the globe using computed tomography and magnetic resonance imaging. *Israel J Med Sci* 1992;28:145-152.
  10. Mafee MF. Uveal melanoma, choroidal hemangioma, and simulating lesions. Role of MR imaging. *Radiol Clin North Am* 1998;6:1083-1099.
  11. Wycliffe ND, Mafee MF. Magnetic resonance imaging in ocular pathology. *Top Magn Reson Imaging* 1999;10:384-400.
  12. Kuhl CK, Miellecareck P, Klaschick S, et al. Dynamic breast MR imaging: Are signal intensity time course data useful for differential diagnosis of enhancing lesions? *Radiology* 1999;211:101-110.
  13. Gilles R, Guinebretiere JM, Lucidarme O, et al. Nonpalpable breast tumors: diagnosis with contrast-enhanced subtraction dynamic MR imaging. *Radiology* 1994;191:625-631.
  14. Boetes C, Barentsz JO, Mus RD, et al. MR characterization of suspicious breast lesions with enhanced TurboFLASH subtraction technique. *Radiology* 1994;193:777-781.
  15. Yang S, Law M, Zagzag D, et al. Dynamic contrast-enhanced perfusion MR imaging measurements of endothelial permeability: Differentiation between atypical and typical meningiomas. *Am J Neuroradiol* 2003;24:1554-1559.
  16. Berger MS. Perfusion MR and the evaluation of meningiomas: Is it important surgically? *Am J Neuroradiol* 2003;24:1499-1500.
  17. Molls M, Feldmann J, Sievers K. Clinical investigations on blood perfusion in human malignancies of the pelvis and abdomen: significance for tumor therapy. In: Steiner R, et al, eds. *Angiogenesis: Key Principles*. Basel, Switzerland: Birkhauser Verlag; 1992:368-372.
  18. Degani H, Chetrit-Dadiani M, Bogin L, et al. Magnetic resonance imaging of tumor vasculature. *Thromb Haemost* 2003;89:25-33.

